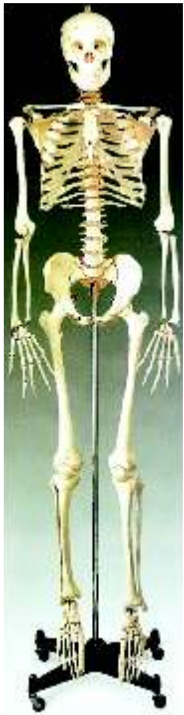

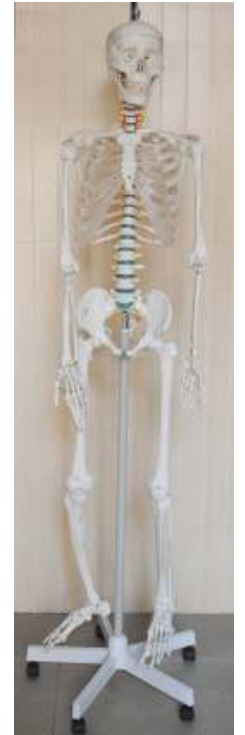Anatomy Models & Skeletons

IMP- 126 IMPORTED SKELETON (USA)

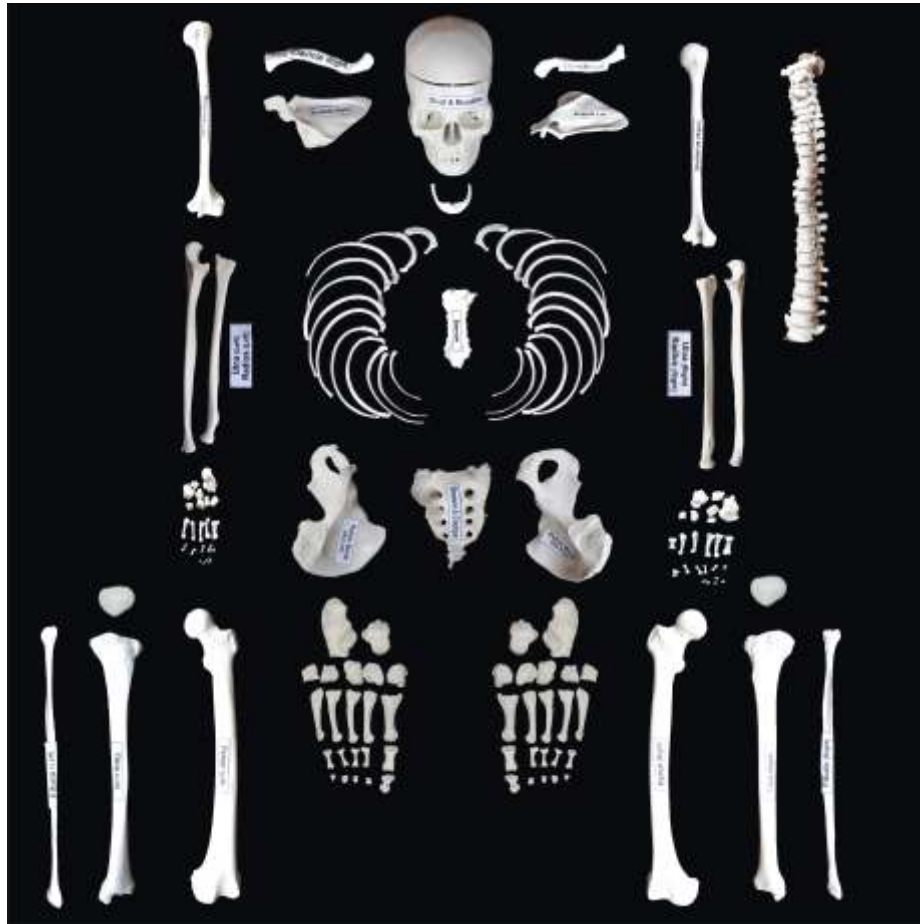

Male

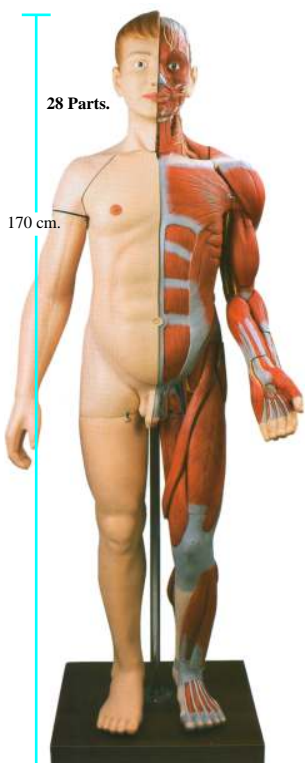
IMP- 126 F IMPORTED SKELETON (USA)



Female



IMP 2 Human Body Muscles with Internal organs

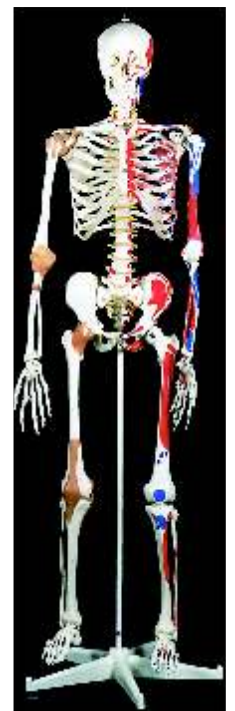

All Skeleton Parts are Near to Original

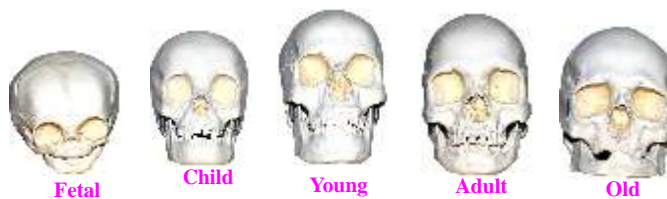Full skeleton complete (Loose Bones)

- Skull With Mandible 3parts
- Ribs (L&R)
- Sternum
- Humerus, Radius, Ulna (Left)
- Humerus, Radius, Ulna (Right)
- Pelvis (L&R)
- Sacrum
- Femur, Tibia, Fibula (Left)
- Femur, Tibia, Fibula (Right)
- Vertebral Column (Disarticulated)
- Cervical Vertebrae (Set of 7)
- Thoracic Vertebrae (Set of 12)
- Lumbar Vertebrae (Set of 5)
- Hand Disarticulated (L&R)
- Foot Disarticulated (L&R)

IMP- 127 IMPORTED MR. SUPERSKELTON (USA)



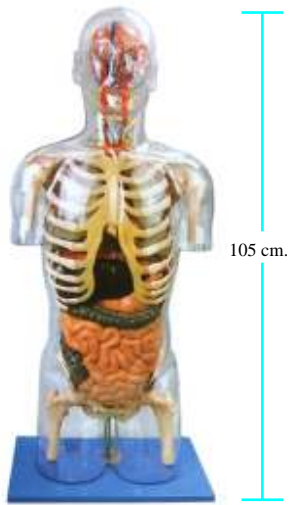
IMP 260 Comparative Study of Skulls, Set of 5



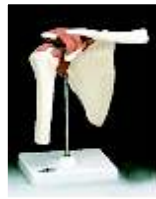Joint



IMP 3 Transparent Torso With Internal Organs



A-88 Imported FUNCTIONAL SHOULDER JOINT (RIGHT)



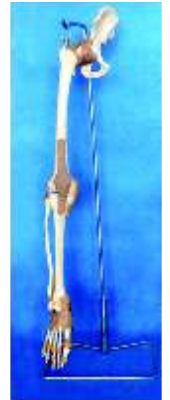A-89 Imported FUNCTIONAL HIP JOINT (RIGHT)



A-90 Imported FUNCTIONAL ELBOW JOINT (RIGHT)



A-86 Imported ADULT LEG BONE WITH THREE JOINTS & LIGAMENTS Without Stand



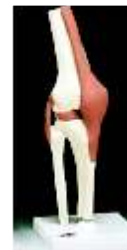A-91 Imported FUNCTIONAL WRIST JOINT (RIGHT)



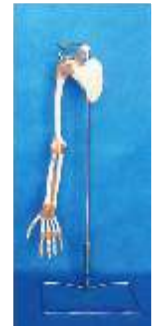A-92 Imported FUNCTIONAL ANKLE JOINT (RIGHT)



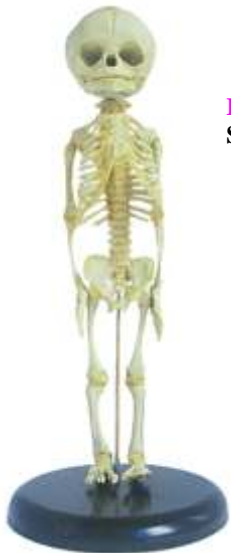A-93 Imported FUNCTIONAL KNEE JOINT (RIGHT)



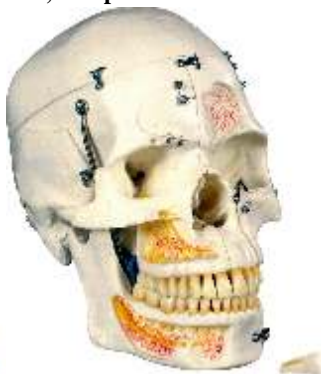A-87 Imported ADULT ARM BONE WITH THREE JOINTS & LIGAMENTS Without Stand



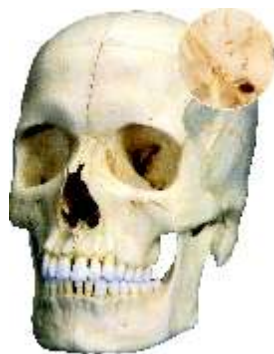IMP126A Fetus Skeleton Model



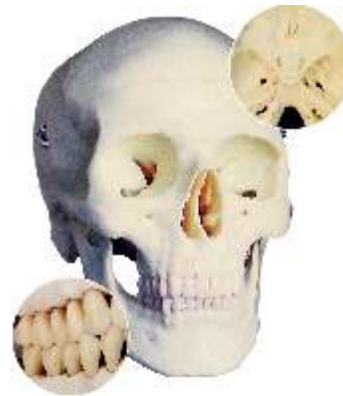IMP 255 Deluxe Demonstration Skull, 10 - parts



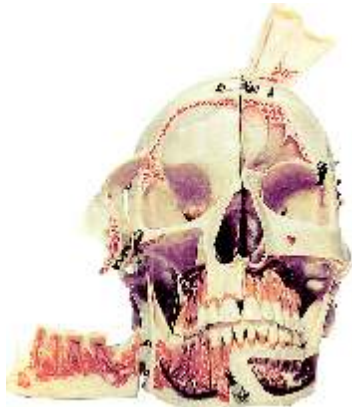IMP 256 System Skull - Bony Skull, 6-part



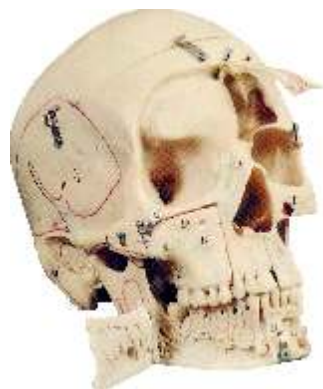IMP 257 Classic Skull, 3-part



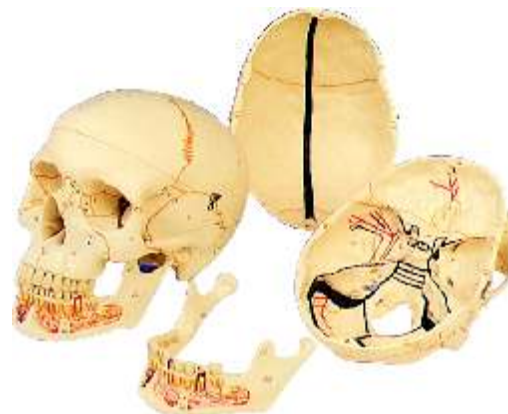IMP 251 Skull model decomposable into ten parts with anatomical parts highlighted through colour.



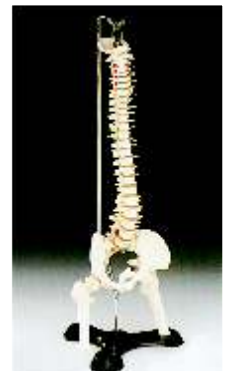IMP 252 Skull decomposable into ten parts with anatomical parts highlighted through colours.



IMP 258 Classic Skull, with opened Lower jaw, 3-part



IMP.131 IMPORTED VERTEBRAL COLUMN WITH FEMORAL HEADS & STAND :



Slides



IMP287 MICRO anatomy
Artery and Vein



IMP 282 MICRO
Anatomy Liver



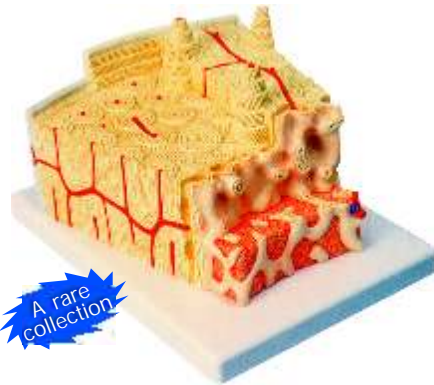
IMP 284 MICRO Anatomy
Kidney



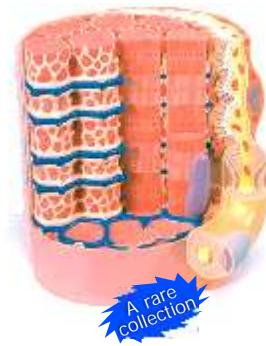IMP 286 MICRO Anatomy
Digestive System



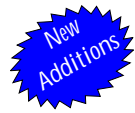IMP281 MICRO anatomy
Bone Structure



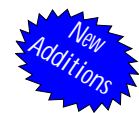IMP 289 Micro Anatomy
Muscle Fibre



IMP 285 MICRO Anatomy Eye



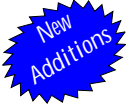German Imported Human Microscopic Histology Slides



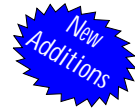- HHS01 Adipose Tissue
- HHS02 Hyaline Cartilage
- HHS03 Elastic Cartilage
- HHS04 White Fibro Cartilage
- HHS05 Bone T.S.
- HHS06 Bone L.S.
- HHS07 Skeletal Muscle
- HHS08 Smooth Muscle
- HHS09 Cardiac Muscle
- HHS10 Peripheral Nerve T.S.
- HHS11 Peripheral Nerve L.S.
- HHS12 Sensory Ganglion
- HHS13 Dorsal root ganglion
- HHS14 Elastic artery
- HHS15 Muscular Artery
- HHS16 Large vein
- HHS17 Small vein
- HHS18 Lymph node
- HHS19 Thymus
- HHS20 Platine tonsil
- HHS21 Spleen

- HHS22 Tongue filli form and fungi from papillae
- HHS23 Tongue circumvellate papillae
- HHS24 Oesophagus
- HHS25 Stomach-fundus
- HHS26 Stomach-pylorus
- HHS27 Duodenum
- HHS28 Jejunum
- HHS29 Ileum
- HHS30 Large Intestine
- HHS31 Appendix
- HHS32 Liver
- HHS33 Gall Bladder
- HHS34 Pancreas
- HHS35 Salivary Gland-serus
- HHS 36 Salivary Gland-mixed
- HHS37 Salivary Gland-mucus
- HHS38 Trachea
- HHS39 Lung
- HHS40 Thyroid with para thyroid
- HHS41 Pitutary gland
- HHS42 Adrenal Gland

- HHS43 Kidney
- HHS44 Ureter
- HHS45 Urinary bladder
- HHS46 Testis
- HHS47 epididymis
- HHS48 Vas deferens
- HHS49 Prostate Gland
- HHS50 Ovary
- HHS51 Uterus
- HHS52 Uterine tube
- HHS53 Thin Skin
- HHS54 Thick Skin
- HHS55 Cornea
- HHS56 Retina
- HHS57 Spinal Cord
- HHS58 Cerebrum
- HHS59 Cerebellum
- HHS60 Placenta
- HHS61 Umbilical Cord
- HHS62 Mammary Gland



USA Imported Human Microscopic Histology Slides



- | | | | | | |
|-----|---|-----|--|------|---|
| C01 | Simple squamous Epithelium sec. | C34 | Stomach fundic portion sec. | C67 | Fallopian Tube sec |
| C02 | Simple Cuboidal Epithelium sec. | C35 | Stomach Cardiac Region sec. | C68 | Penis c.s |
| C03 | Simple Columna Epithelium sec. | C36 | Stomach Pyloric Region sec. | C69 | Cervix sec. |
| C04 | Columna Pseudo stratified ciliated epithelium | C37 | Small Intestine c.s | C70 | Thyroid Gland sec |
| C05 | Stratified squamous Epithelium sec | C38 | Duodenum sec. | C71 | Thymus Gland sec |
| C06 | Transitinal Epithelium sec | C39 | Jejunum sec. | C72 | Mammary gland sec |
| C07 | Ciliated Epithelium | C40 | Ileum c.s. show villi and goblet cells | C73 | Adrenal Gland sec |
| C08 | Epidermis from human mouth | C41 | Appendix sec. | C74 | Lymph Node sec |
| C09 | Glandular Epithelium sec | C42 | Large Intestine sec | C75 | Salivary gland c.s. |
| C10 | Loose Connective Tissue w.m | C43 | Colon sec. | C76 | Cerebrum sec |
| C11 | Dense Connective Tissue w.m | C44 | Rectum sec. | C77 | Cerebellum sec |
| C12 | Adipose Tissues sec. | C45 | Pancreas sec. | C78 | Pituitary gland c.s. |
| C13 | Hyaline Cartilage sec. | C46 | Spleen sec. | C79 | Tendon teased c.s. |
| C14 | Elastic Cartilage sec. | C47 | Liver sec. | C80 | Eye entail sec |
| C15 | Fibro Cartilage sec. | C48 | Gall Bladder sec | C81 | Eyeball sec |
| C16 | Human Chromosome Nonmal Female w.m | C49 | Fat layer | C82 | Human Skin sec. show Thick Cornifie Layer |
| C17 | Human Chromosome Nonmal Male w.m | C50 | Fibroblast | C83 | Human Skin sec. Through sweat Gland |
| C18 | Medulla oblongata sec | C51 | Nerve cells | C84 | Human Skinsec. Through Hair Folicle |
| C19 | Red marrow smear | C52 | Brochiolus | C85 | White fibrous tissue |
| C20 | Smooth Muscle Teased Preparation w.m | C53 | Lung sec | C86 | Mucous tissue ,umbilical cord |
| C21 | Blood smear | C54 | Artery sec | C87 | Decalcified bone c.s. |
| C22 | Hair | C55 | Vein sec | C88 | Infant developing bone section |
| C23 | Smooth Muscle l.s and c.s | C56 | Large artery sec | C89 | Developing membrane bone |
| C24 | Skeletal Muscle l.s and c.s | C57 | Large vein sec | C90 | Muscle-tendon junction l.s. |
| C25 | Cardiac Muscle sec | C58 | Heart l.s.whole | C91 | Muscle spindle |
| C26 | Spinal Card l.s and c.s | C59 | Kidney l.s | C92 | Nerve bundle |
| C27 | Sciatic nerve l.s. | C60 | Kidney with Blood Vessel Injected sec. | C93 | Sympathetic ganglion |
| C28 | Motor neuron w.m | C61 | Ureter sec. | C94 | Motor cortex section |
| C29 | Motor Nerve Endings w.m | C62 | Ovary sec. | C95 | Sentor cortex |
| C30 | Tongue l.s. show filiform papilla | C63 | Placenta Human sec. | C96 | Cerebellar cortex |
| C31 | Esophagus sec. | C64 | Human Sperms smear | C97 | Palatine tonsil |
| C32 | Trachea sec. | C65 | Epididymis sec | C98 | Thin skin from human palm section |
| C33 | Stomach sec. | C66 | Prostate Gland Human sec. | C99 | Finger nail section |
| | | | | C100 | Stomach -duodenal junction l.s. |